Dupilumab Induces Rapid and Sustained Improvement in Clinical Signs in Children With Severe Atopic Dermatitis

Amy S. Paller[1,2], Elaine C. Siegfried[3,4], Peter D. Arkwright[5], Rui Huang[6], Haixin Zhang[6], Noah A. Levit[6], Karli Rosner[7], Ana B. Rossi[7]

[1]Northwestern University Feinberg School of Medicine, Chicago, IL, USA; [2]Ann and Robert H. Lurie Children's Hospital, Chicago, IL, USA; [3]Saint Louis University, St. Louis, MO, USA; [4]Cardinal Glennon Children's Hospital, St. Louis, MO, USA; [5]Lydia Becker Institute of Immunology & Inflammation, University of Manchester, Manchester, UK; [6]Regeneron Pharmaceuticals, Inc., Tarrytown, NY, USA; [7]Sanofi Genzyme, Cambridge, MA, USA

BACKGROUND

- Dupilumab provides significant clinical improvement with an acceptable benefit–risk profile in adults[1] and adolescents[2] with moderate-to-severe atopic dermatitis (AD) and in children aged ≥ 6 – < 12 years with severe AD inadequately controlled with topical medications[3]

OBJECTIVE

- **To evaluate the effect of dupilumab treatment on AD signs by anatomical region in children aged ≥ 6 – < 12 years with severe AD**

METHODS

Study design

- LIBERTY AD PEDS (NCT03345914)[3] was a phase 3, double-blinded trial in which children aged ≥ 6 – < 12 years with severe AD received dupilumab + topical corticosteroids (TCS) or placebo + TCS (**Figure 1**)
- Here, we assess the AD signs erythema, infiltration/papulation, excoriations, and lichenification in 4 anatomical regions – head and neck, trunk, upper extremities, and lower extremities – in the subsets of patients who received FDA-approved doses of dupilumab

Figure 1. Study design.

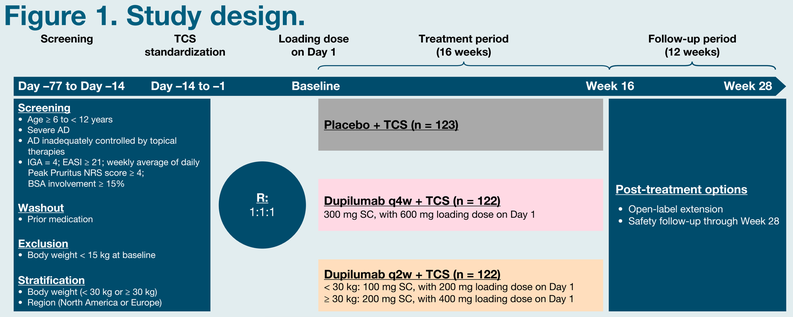

BSA, body surface area; EASI, Eczema Area and Severity Index; IGA, Investigator's Global Assessment; NRS, Numerical Rating Scale; q2w, every 2 weeks; q4w, every 4 weeks; R, randomization; SC, subcutaneous.

Outcomes

- Least squares (LS) mean % change from baseline in AD signs as measured by EASI, by anatomical region, at Week 4 and Week 16
  - The last observation carried forward method was used with censoring after rescue treatment use

RESULTS

- Baseline demographics and disease characteristics are shown in the **Table**
- Significant improvements in all signs across anatomical regions occurred as early as Week 4; improvement continued through Week 16 (**Figure 2**)

Safety

- Dupilumab was generally well tolerated, and safety was consistent with the safety profile observed in adults and adolescents[1–3]
- Most common adverse events were conjunctivitis and injection site reactions[3]

CONCLUSION

- **Dupilumab treatment induced similar rapid and consistent improvements in erythema, infiltration/papulation, excoriations, and lichenification across 4 anatomical regions in children with severe AD**

Table. Baseline demographics and disease characteristics.

	< 30 kg		≥ 30 kg	
	Dupilumab 300 mg q4w + TCS (n = 61)	Placebo + TCS (n = 61)	Dupilumab 200 mg q2w + TCS (n = 59)	Placebo + TCS (n = 62)
Age, mean (SD), years	7.5 (1.4)	7.1 (1.3)	9.5 (1.4)	9.5 (1.3)
Male sex, n (%)	27 (44.3)	30 (49.2)	33 (55.9)	31 (50.0)
Weight, mean (SD), kg	23.8 (3.0)	23.3 (3.4)	40.2 (10.0)	39.5 (9.5)
Duration of AD, mean (SD), years	6.8 (1.7)	6.3 (1.7)	8.1 (2.3)	8.0 (2.2)
EASI total score, mean (SD) (range: 0–72)	36.9 (12.4)	38.9 (12.6)	37.1 (11.8)	39.0 (11.5)
Mean sign score (SD) (range: 0–3)				
Erythema	2.5 (0.5)	2.5 (0.6)	2.6 (0.5)	2.7 (0.5)
Infiltration/papulation	2.6 (0.5)	2.6 (0.6)	2.5 (0.6)	2.5 (0.6)
Excoriations	2.6 (0.6)	2.5 (0.6)	2.4 (0.6)	2.4 (0.6)
Lichenification	2.6 (0.5)	2.7 (0.5)	2.7 (0.5)	2.7 (0.5)

SD, standard deviation.

Figure 2. LS mean % change in EASI components by body region (head and neck, trunk, upper extremities, and lower extremities) from baseline through Week 16, with patient images[a,4] before and after treatment.

*$P < 0.05$; **$P < 0.01$; ***$P < 0.001$; ****$P < 0.0001$ vs placebo. [a]These are individual patients and not representative of results from all patients.

References: 1. Simpson EL, et al. JAMA Dermatol. 2019;156:44-56. 2. Simpson EL, et al. N Engl J Med. 2016;375:2335-48. 3. Paller AS, et al. J Am Acad Dermatol. 2020;83:1282-93. 4. Shumel B, Rossi AB. Dermatologist. 2020;12:42-6.

Acknowledgments: Research sponsored by Sanofi and Regeneron Pharmaceuticals, Inc. ClinicalTrials.gov identifier: NCT03345914. Medical writing/editorial assistance provided by Anne Slomp, PhD, of Excerpta Medica, funded by Sanofi Genzyme and Regeneron Pharmaceuticals, Inc.

Disclosures: Paller AS: AbbVie, Eli Lilly, Galderma, Incyte, Janssen, Lenus, LEO Pharma, Novartis, Regeneron Pharmaceuticals, Inc. – investigator; Almirall, Amgen, Asana Biosciences, BMS, Boehringer Ingelheim, Castle Creek Biosciences, Dermavant, Dermira, Eli Lilly, Exicure, Forte, Galderma, Lenus, LEO Pharma, Meda, Meiji Seika, Novan, Novartis, Pfizer, Regeneron Pharmaceuticals, Inc., Sanofi Genzyme, Sol Gel, UCB Biopharma – consultant. **Siegfried EC:** Dermavant, Eli Lilly, Pfizer, Regeneron Pharmaceuticals, Inc., Verrica – consultant; GSK, LEO Pharma, Novan – data and safety monitoring board member; Eli Lilly, Janssen, Regeneron Pharmaceuticals, Inc., Stiefel, Verrica – Principal Investigator in clinical trials. **Arkwright PD:** Regeneron Pharmaceuticals Inc. – investigator; Sanofi Genzyme – research grant, advisor. **Huang R, Zhang H, Levit NA:** Regeneron Pharmaceuticals, Inc. – employees and shareholders. **Rosner K, Rossi AB:** Sanofi Genzyme – employees, may hold stock and/or stock options in the company.

Presented at the Revolutionizing Atopic Dermatitis Conference (RAD 2020); Virtual Conference; December 13–14, 2020.